

First Time in India the Coronary Stenting

First Time in India the Coronary Stenting made of Tantalum (Strecker Company) was implanted in about July, 1991 by Dr. P. Lal. This helps in preventing re-occurrence after the angioplasty. It was implanted on 52 yrs old patient Mr. Ismail Maniku from Maldives (Father in Law of the President of Maldives). Patient complained of unstable angina and underwent balloon angioplasty of RCA. Patient suffered from acute occlusion of the Right Coronary Artery. A stent was implanted successfully as a bailout device at Apollo Hospital, Chennai.

1. A stent was implanted successfully as a bailout device. The procedure was done by Dr. Lal at Apollo Hospital, Chennai around about in June 1991. The patient is now 79 yrs. old and still comes to Dr. Lal for follow-up in Metro Hospital & Heart Institute, Noida. (Certificate for 1st time in India is attached).


Dr. Lal was trained in Germany along with Dr. H. Sievert to such kind of procedures. The following were the presentations given by **DR. LAL about CORONARY STENTING FOR THE FIRST TIME IN THE COUNTRY :-**

- a) Role of stent in unstable angina at the annual meeting of Cardiological Society of India held in Hyderabad in 1991 where Dr. Lal demonstrated the use of coronary stent as a bailout situation in setting of acute occlusion of the artery the incidence of which used to be 1-3% following the balloon angioplasty.
- b) Dr. Lal presented the Scientific paper on coronary stenting for the first time in the country.
- c) Dr. Lal delivered the first lecture of the country on coronary stenting at the main hall during annual meeting of Cardiological Society of India in 1992.
- d) Dr. Lal also presented the actual procedures of stenting and advantage of Tantalum stents over other metallic stents due to its radio-opacity during his Dr. V.V. Shah Oration awarded by Cardiological Society of India in 1992.

PUBLICATION

Paper Presented and published in Indian Heart Journal (**1st Scientific Paper of the Country on Coronary Stenting**).

- ☒ Lal et al. Out Initial Experience with Tantalum Coronary stent [Abstract]. Indian Heart Journal, Vol. No, 1991; 135.
- ☒ P Lal, P Jain, PT Upasani : Intracoronary Stenting Using Long Stents (abstracts). Indian Heart Journal 48:538, 1996
- ☒ P Lal, PT Upasani, SM Sachdeva, S Kanwar : Non-Randomized Comparison of Various Treatment Modalities for Restenosis Following Coronary Angioplasty (abstract) Int. Journal of Cardiovascular Interventions 4 (Suppl 1) : 34, 2001.
- ☒ P Lal, PT Upasani, AK Pandey, S Kanwar : Initial Experience with Lunar Star lex (Iridium Oxide-Coated) Coronary Stent for Prevention of Restenosis after Coronary Angioplasty (abstract). Indian Heart Journal 54:598, 2002.
- ☒ P Lal, Upasani AK Pandey, S Kanwar: Use of Stenting for In-Stent Restenosis – Is it Justified (abstract) Ind. Heart Journal 54:597, 2002
- ☒ P Lal, PT Upasani, AK Pandey, SC Manchanda, P Arora, S Kanwar : Efficacy of Drug Eluting Stents in Patients with Diabetes Mellitus. Indian Heart Journal 55:448, 2003



**Patient Ismail
Maniku**

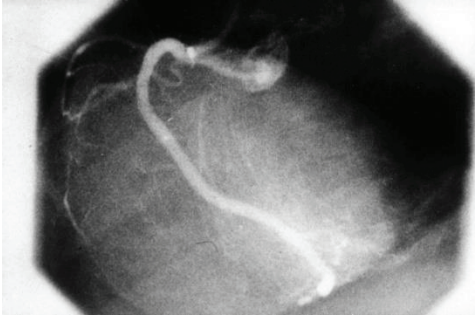
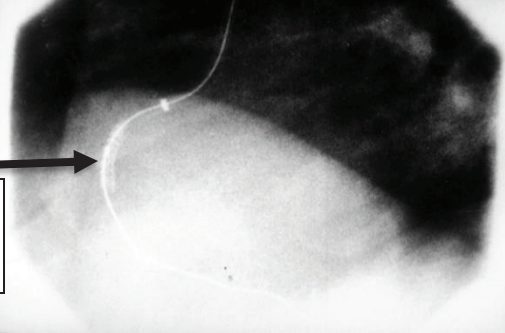
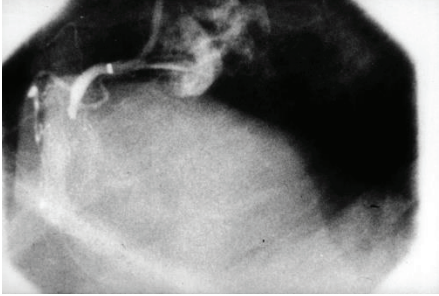
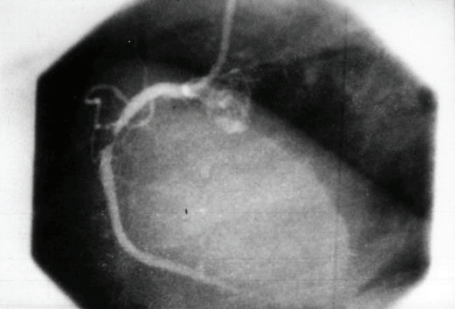
14th November 2018

TO WHOM IT MAY CONCERN

Reg. Implantation of first coronary stent in the country

It is my pleasure to confirm that I have been a patient of Dr. P.Lal since 1991 when I suffered some cardiac problems. He did angiography in the month of June 1991 followed by balloon angioplasty to address the block on the right artery of my heart. After 3-4 days I had chest discomfort, and he performed an angiography again and found that the same artery was blocked. To save my life he placed a stent in my right coronary artery successfully. I fully remember that it was the first coronary stent in the entire country that he placed in my heart and his achievement was celebrated. I felt very proud and happy for him too. Since then I have been coming to consult Dr. Lal from Maldives to Noida periodically. I was 52 yrs at that time when the stent was placed and now I am 79 yrs and in excellent health. Dr. Lal is a great doctor and I wish him all the best.

Ahmed Ismail
NO. 23 ST KILDA'S LANE
COLOMBO, SRI LANKA



**1st Coronary Stent of
the Country.**

**Still Images from the Procedure of the patient
Mr. Ismail in 1-4 Parts**